

Uterine Artery Embolization under Electroacupuncture for Uterine Leiomyomas

João M. Pisco, MD, Mitsuharu Tsuchiya, MD, Tiago Bilhim, MD, Marisa Duarte, MD, Daniela Santos, MD, and Antonio G. Oliveira, MD

PURPOSE: To evaluate whether electroacupuncture is a safe and effective alternative to pharmacologic sedation/analgesia in uterine artery embolization (UAE) for leiomyomas.

MATERIALS AND METHODS: A nonrandomized prospective study was undertaken in 70 consecutive patients (mean age, 39.5 years) undergoing UAE with polyvinyl alcohol (PVA) particles between August 2006 and January 2007. Thirty-three patients chose to undergo UAE under electroacupuncture anesthesia (EAA; group A) and 37 were treated under local pharmacologic anesthesia (group B). Pain scores (rated from 0 to 10) in both groups were compared during and after the procedure. The outcome of UAE was evaluated at 6 months.

RESULTS: Mean pain scores during embolization were 0.36 in group A and 0.84 in group B; scores after embolization and before discharge were 3.00 in group A and 4.49 in group B; and scores at discharge were 0.97 in group A and 2.11 in group B. These differences were statistically significant after embolization and at hospital discharge ($P = .02$ and $P = .0001$, respectively). All patients except one in each group were discharged from the hospital 4–8 hours after UAE; the two who remained longer had severe pain. There were no significant differences in clinical outcomes, nor in uterine and leiomyoma volumes, at discharge and at 6 months ($P > 0.99$ and $P = .72$, respectively).

CONCLUSIONS: There was a statistically significant postembolization pain reduction in patients treated under EAA versus local pharmacologic anesthesia and no differences in UAE outcomes between groups at 6 months.

J Vasc Interv Radiol 2009; 20:863–870

Abbreviations: EAA = electroacupuncture anesthesia, PVA = polyvinyl alcohol, UAE = uterine artery embolization

FROM a societal economic perspective, uterine artery embolization (UAE) has proven to be the best treatment strategy in women with symptomatic uterine leiomyomas (1). UAE in women with symptomatic leiomyomas leads to long-

term symptom relief (2) with a durable improvement in quality of life. These results are achievable when the procedure is performed in any experienced community or academic interventional radiology practice (3).

However, most patients experience several hours of moderate to severe pain after this procedure, with recurrent or prolonged severe pain in some occasions (4). Changes in pain control protocol, as well as a trend toward less extensive occlusion of the uterine vasculature, have made this problem less common (4). There are many different strategies and simplified protocols for pain control during and after UAE (5–10).

Acupuncture has proven to be associated with improvements in pain and quality of life in patients with dysmenorrhea and to be a cost-effective option (11). Also, high-frequency transcutaneous electrical nerve stimulation has

proven to be effective for the treatment of dysmenorrhea (12). However, we are aware of no studies to date that report the use of acupuncture as a pain control method for UAE.

Electroacupuncture, also known as percutaneous electrical nerve stimulation, involves small clips (one positive and one negative) attached to two needles on one end and to a small box outputting in a electrostimulator on the other end. It is used to strengthen the effect of an acupuncture treatment or to deal with nerve pain or other neurologic problems (eg, Bell's palsy). The use of an electrostimulator attached to the needles is a mean of stimulating the acupoints. Stimulation increases levels of analgesia, promotes tissue repair and healing, and promotes regeneration of nerve fibers in situations in which cell bodies of damaged nerves are still vital.

From the Department of Radiology (J.M.P., M.T., T.B.), St. Louis Hospital; University Departments of Radiology (J.M.P., T.B.) and Biostatistics (A.G.O.), Faculty of Medical Sciences, New University of Lisbon; Department of Radiology (M.D.), Pulido Valente Hospital, Lisbon; and Department of Surgery (D.S.), Cascais Hospital, Cascais, Portugal. Received October 5, 2008; final revision received February 20, 2009; accepted March 20, 2009. **Address correspondence to** J.M.P., Rua Luz Soriano, n°182, 1200-249, Lisbon, Portugal; E-mail: joao.pisco@hvp.min-saude.pt

From the SIR 2009 Annual Meeting.

None of the authors have identified a conflict of interest.

© SIR, 2009

DOI: 10.1016/j.jvir.2009.03.045

The aim of this study is to evaluate whether electroacupuncture anesthesia (EAA) is a safe and effective alternative to the use of subcutaneous anesthesia on the puncture site and antiinflammatory and analgesic pharmacologic sedation/analgesia in UAE for uterine leiomyomas.

MATERIALS AND METHODS

Patients

From August 2006 to January 2007, we conducted a nonrandomized prospective study in 70 consecutive patients who were being treated with UAE for symptomatic leiomyomas. Thirty-three patients chose to undergo UAE under EAA without any local anesthesia (group A) and the remaining 37 were treated under local anesthesia (group B). The decision to include patients in group A or B was based only on patient preference. The age range of patients was 27–56 years (mean age, 39.5 y). Sixty-two patients were white and eight were black. The mean age of patients treated under EAA was 37.5 years \pm 6.2 (SD) and that of patients treated under local anesthesia was 41.4 years \pm 6.8 (P = .015). There were no other statistically significant differences in the baseline data between groups (Table 1).

The main indications for UAE were menorrhagia, bulk-related symptoms, and pain (Table 1). There were no cases of concomitant adenomyosis. Patients seeking future fertility were not excluded. The study was approved by the institutional review board. All patients gave written informed consent. Neither the patients nor the operator were blinded to the technique being used.

Preprocedural Assessment

Contrast-enhanced pelvic magnetic resonance (MR) imaging was performed in every patient before embolization to evaluate baseline volume of the uterus and of the largest leiomyoma via the formula for a prolate ellipse (ie, length \times depth \times width \times 0.5233). Contrast-enhanced pelvic MR imaging was performed with a 1.5-T system (Philips, Best, The Netherlands). Axial, sagittal, and coronal imaging examinations were performed with turbo spin-echo T2-weighted imaging. T1-weighted MR

Table 1
Summary of Baseline Data

Variable	Group A (n = 33)	Group B (n = 37)	P Value*
Mean (\pm SD) age (y)	37.5 \pm 6.2	41.4 \pm 6.8	.015
Menorrhagia	19 (57.6)	23 (62.2)	>.99
Bulk symptoms	9 (27.3)	10 (27.2)	>.99
Pain	5 (15.2)	4 (10.8)	.79
Uterine volume (cm ³)	540	445	.52
Tumor volume (cm ³)	210	134	.39
No. of tumors			.68
1	11 (33.3)	15 (40.5)	
2–5	4 (12.1)	6 (16.2)	
>5	18 (54.5)	16 (43.2)	
Dominant tumor location			.59
Subserosal	4 (12.1)	2 (5.4)	
Intramural	23 (69.7)	27 (73.0)	
Submucosal	6 (18.2)	9 (24.3)	

Note.—Values in parentheses are percentages.

* Fisher exact test.

images and axial and sagittal images were obtained before and after gadolinium injection (2 mL/sec). MR angiography was performed with the use of specific software to detect contrast agent arrival.

Periprocedural Medications

Preembolization medication was the same in both groups. Patients were given an acid-suppressing drug (oral omeprazole 20 mg), an antiinflammatory drug (oral diclofenac potassium 50 mg; Novartis, East Hanover, New Jersey), an antihistamine (oral hydroxyzine 25 mg; Atarax; UCB, Brussels, Belgium), and a laxative (sodic docusate 10 mg and sorbitol 1,340 mg as suppositories) twice (at breakfast and dinner) on the day before and once (at breakfast) on the day of UAE.

Just before embolization, patients in group A (ie, EAA group) received anxiolytic (diazepam 5 mg sublingual) and antiinflammatory (intravenous piroxicam 20 mg) medication and patients in group B (ie, local anesthesia group) received the same plus intravenous omeprazole 20 mg, analgesic agents (intravenous metamizol 2 g [dipyrone] and intravenous tramadol 100 mg), and antiemetic agents (intravenous metoclopramide 25 mg [Primperan; Sanofi-Aventis, Porto Salvo, Portugal] and droperidol 0.1 mg [Janssen-Cilag, Barcarena, Portugal]).

EEA Technique

For EEA, electric stimulation at bilateral acupoints ST 36 (ie, upper third of external leg) and SP 6 (ie, lower third of internal leg) was given with an EAA apparatus (Figs 1, 2). ST 36 refers to acupoint stomach 36 and SP 6 refers to acupoint spleen 6—these correspond to “Zu San Li” and “Sanyinjiao,” respectively, in Chinese; and “Ashi san ri” and “San in ko,” respectively, in Japanese—which belong, respectively, to the stomach meridian and spleen meridian. The meridians are considered to be energy channels that flow through the body; they are paired, and according to Chinese traditional medicine, there are 12 main meridians—lungs, large intestine, stomach, spleen, heart, small intestine, bladder, kidneys, pericardium, triple heater/abdomen, gall bladder, and liver—plus eight extra meridians.

For the present purpose, needles were connected through wires to an electrostimulator (Fig 3) that sent an electrical pulse (15–20 Hz, 6 V). For analgesia, the procedure was started 20–30 minutes after insertion of the needles and the electroacupuncture was continued for 30 minutes after UAE.

UAE Technique

Patients in group B were given local anesthesia with Xylocaine 1% (B. Braun, Melsungen, Germany) at the puncture site (ie, right inguinal zone).

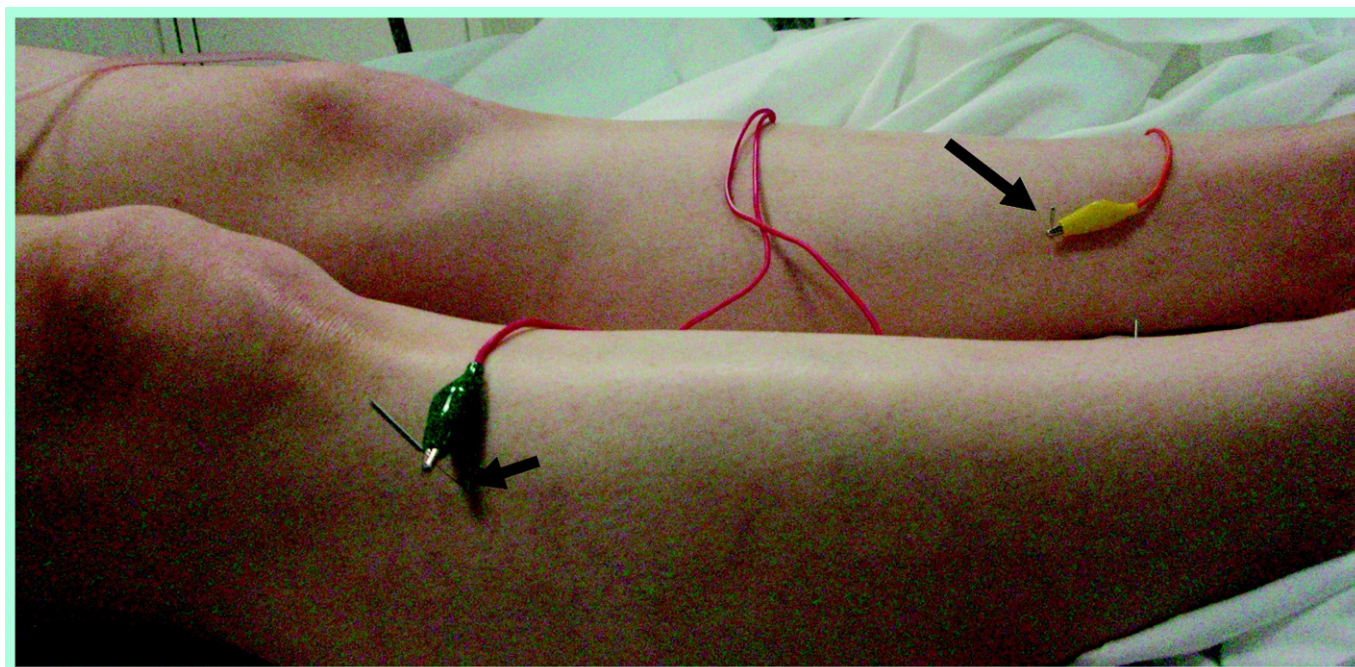


Figure 1. Legs of a patient with needles placed at anesthesia points ST 36 point (short arrow) and SP 6 point (long arrow)—the most important points for anesthesia—and connected to wires. (Available in color online at www.jvir.org.)

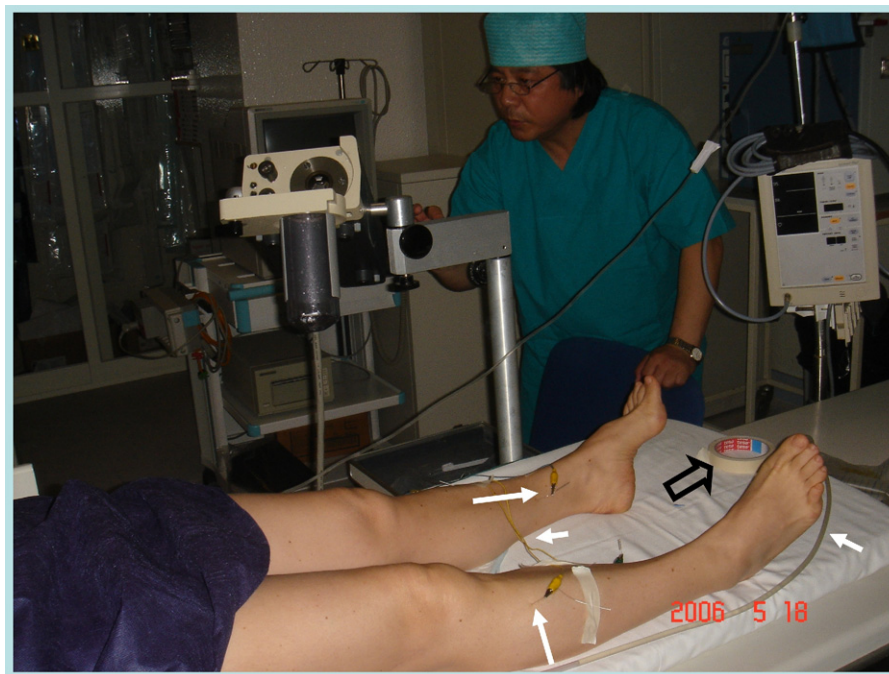

Figure 2. Needles at anesthesia points (large white arrows) connected through wires (small white arrows) to an electrostimulator (open arrow). (Available in color online at www.jvir.org.)

No local subcutaneous anesthesia was used in patients in group A.

To perform UAE, a single right fem-

oral approach was used and both uterine arteries were embolized with a 5-F Cobra-shaped catheter and a hydro-

philic guide wire. Microcatheters were used only when necessary. To catheterize the right uterine artery, a Waltman loop was formed. The uterine arteries of the patients in both groups were embolized with nonspherical polyvinyl alcohol (PVA) particles (Contour; Boston Scientific, Natick, Massachusetts) mixed with an antiinflammatory agent (ketoprofen 100 mg). The total amount of PVA used in each group was registered. Embolization was started with a vial of 300–500- μ m PVA particles for each uterine artery and completed with vials of 500–700- μ m PVA particles, with the amount of embolic material used in each patient recorded. The endpoint chosen for embolization was slow flow or near-stasis in the main uterine artery, as shown by a lack of filling of arterial branches to the leiomyomas, interruption of flow in the uterine artery, or contrast agent reflux toward the origin of the uterine artery.

During embolization, the patients in both groups received an intravenous anxiolytic drug (midazolam 0.5 mg) if necessary. Patients in group B also received an antiinflammatory drug (intravenous ketorolac tromethamine 30 mg; Toradol, Roche, Nutley, New Jersey) twice before the embolization of each uterine artery.




Figure 3. Electrostimulator with wires connected. (Available in color online at www.jvir.org.)

Upon completion of the embolization, patients in group A received intravenous medication with the following: acid-suppressing drug (omeprazole 20 mg), analgesic agents (paracetamol 500 mg, tramadol 50 mg, metamizol 1 g), antiinflammatory agent (ketorolac tromethamine 15 mg), and antiemetic drugs (metoclopramide 10 mg, ondansetron 1 mg). Patients in group B received the same dose of intravenous acid-suppressing drug (omeprazole 20 mg) but double the doses of analgesic agents (paracetamol 1 g, tramadol 100 mg, metamizol 2 g) and antiinflammatory drugs (ketorolac tromethamine 30 mg). As antiemetic agents, metoclopramide 25 mg (Primperan; Sanofi-Aventis) and ondansetron 2 mg were administered intravenously.

Patients were asked to rate their pain severity on a numeric pain score scale at the following times: (i) during the procedure, (ii) immediately afterward, (iii) every 2 hours thereafter until discharge, (iv) at discharge, and (v) the following morning. Pain was rated from a score of 0 (indicating no pain) to a score of 10 (indicating the worst pain imaginable). According to the rating recorded, pain was graded as no pain (score 0), light pain (1–2), moderate pain (3–5), severe pain (6–7), or very severe pain (8–10). The most significant (ie, peak) pain score was re-

corded from each patient. Scores of symptoms were compared between groups (Table 2).

Other postembolization symptoms were also registered during the hours after embolization, at discharge, and the following morning. Complications were also assessed according to Society of Interventional Radiology reporting standards (13).

The standard protocol for both groups was same-day discharge when possible (4–8 hours after embolization). Two to 3 hours after the procedure, all asymptomatic patients and those with mild symptoms without nausea or vomiting had a light meal and started oral medication with tramadol 37.5 mg plus paracetamol 325 mg and were discharged 4–8 hours after embolization. Just before discharge, intravenous tramadol 100 mg and metoclopramide 25 mg were given to every patient.

The medication was the same at discharge for both groups. Patients were given daily omeprazole 20 mg and hydroxyzine 25 mg, twice-daily levofloxacin 250 mg, thrice-daily diclofenac potassium 50 mg, and docusate suppositories. As on-demand medication for pain, patients had tramadol 37.5 mg plus paracetamol 325 mg and codeine 30 mg plus paracetamol 500 mg (Dol-U-Ron; Neo-Farmaceutica, Lisbon, Portugal). Dimenhydrinate

100 mg suppositories were used in case of vomiting.

Patient Follow-up

At first consultation, at admission to the hospital, and at discharge, patients were informed verbally and in written form about postembolization constitutional symptoms they could expect, and the corresponding medication. At discharge, patients were given the mobile phone number of the interventional radiologists and two questionnaires to be completed daily for 1 week and again 6 months after the procedure. The patients were questioned concerning their satisfaction with their time of discharge. After being completed, the pain sheets were mailed in.

Overall, the results of embolization were evaluated at 6 months after the procedure by contrast-enhanced pelvic MR imaging, by the answers to the questionnaires, and by clinical observation in 64 patients. Six patients (two from group A and four from group B) were lost to follow-up.

The Fisher exact test, Mann-Whitney *U* test, and Student *t* test were used to compare the clinical presentation and postembolization results between groups. Changes from baseline were compared between groups. Statistically significant differences were assumed at *P* values less than .05.

RESULTS

The technical success rate for bilateral UAE was 98.6% (69 of 70). In one patient from group B, only one uterine artery was embolized as a result of the small size and tortuosity of the other uterine artery. Mean total volumes of PVA particles used per patient were 2.8 mg in group A and 2.7 mg in group B.

There were no differences in puncture site pain between patients who received acupuncture with no subcutaneous anesthesia and those who received local subcutaneous anesthesia.

During embolization, mean pain scores (rated from 0 to 10) were 0.36 in group A (ie, EAA group) and 0.84 in group B (ie, local anesthesia group). Twenty-five patients in group A (76%) and 23 in group B (62%) did not report any pain. Four patients in group B (10.8%) reported moderate pain (ie, score 3–5), compared with none in the

Table 2
Summary of Pain Score

Pain Score	Group A (n = 33)	Group B (n = 37)	P Value*
During UAE			.11
No pain (score 0)	25 (76)	23 (62)	
Light pain (score 1–2)	8 (24.2)	10 (27.0)	
Moderate pain (score 3–5)	0	4 (10.8)	
Severe pain (score 6–7)	0	0	
Mean pain score	0.36	0.84	
After embolization and before discharge			.02
No pain (score 0)	8 (24.2)	4 (10.8)	
Light pain (score 1–2)	5 (15.2)	5 (13.5)	
Moderate pain (score 3–5)	16 (48.4)	15 (40.5)	
Severe pain (score 6–7)	2 (6.1)	6 (16.2)	
Very severe pain (score 8–10)	0	7 (16.9)	
Mean pain score	3.00	4.49	
At discharge			.0001
No pain (score 0)	13 (39.4)	3 (8.1)	
Light pain (score 1–2)	19 (57.6)	28 (75.7)	
Moderate pain (score 3–5)	1 (3.0)	2 (5.4)	
Severe pain (score 6–7)	0	2 (5.4)	
Mean pain score	0.97	2.11	
Morning after UAE			.27
No pain (score 0)	13 (39.4)	12 (32.4)	
Light pain (score 1–2)	18 (54.5)	23 (62.2)	
Moderate pain (score 3–5)	1 (6.1)	2 (5.4)	
Mean pain score	0.82	1.08	

Note.—Values in parentheses are percentages.

* Mann-Whitney *U* test.

other group (Table 2). These differences were not statistically significant ($P = .11$).

The mean pain scores after embolization and before discharge were 3.00 in group A (range, 0–7), and 4.49 in group B (range, 0–10). There were 13 patients with severe or very severe pain in group B, versus only two in group A. There were eight patients (24.2%) without pain and five (15.2%) with light pain (ie, score 1–2) in group A, compared with four (10.8%) without pain and five (13.5%) with light pain in group B (Table 2). These differences were statistically significant ($P = .02$).

At discharge most patients had no pain or light pain, but one in group A (3.0%) and four in group B (10.8%) had pain scores of 3–5. Also, two patients in group B (5.4%) had severe pain (ie, score 6–7) and were treated as outpatients for personal reasons.

The mean pain scores at discharge were 0.97 in group A and 2.11 in group B. This difference was statistically significant ($P = .0001$). One patient from group B was discharged

with severe pain and readmitted because of a persistence of severe pain. None of the other patients required readmission.

All patients were discharged from the hospital 4–8 hours after the procedure, except one patient from each group who had severe or very severe pain. These patients spent the night at the hospital as inpatients and were discharged the next morning, 18 hours later.

There were no other significant differences between groups regarding symptoms at discharge, the next morning, and the next 7 days after UAE. Overall, at discharge, pain scores were 1 or 2 in 47 of 70 patients (67.1%), 3–5 in three patients (4.3%), and 6 or 7 in two patients (2.9%). In addition, fatigue was reported by four patients (5.7%), anorexia by four (5.7%), abdominal swelling by five (7.1%), and vaginal bleeding by six (8.6%; Table 3).

The morning after UAE, the mean pain scores were 0.82 in group A and 1.08 in group B ($P = .27$). Overall, the symptoms the morning after UAE were a pain score of 1 or 2 in 41 of 70

patients (58.6%), fatigue in eight patients (11.4%), anorexia in seven patients (10.0%), vaginal bleeding in seven patients (10.0%), and abdominal swelling in four patients (5.7%). There were no significant differences between groups.

During the 7 days after UAE, seven of the 70 patients (10.0%) reported low-grade fever, seven had abdominal swelling (10.0%), six had vaginal bleeding (8.6%), four had constipation (5.7%), and three had a small inguinal hematoma (4.2%).

Patient satisfaction rates concerning time of discharge were 100% in group A and 98.3% in group B (one patient in this group was dissatisfied by the degree of pain after discharge and consequent readmission).

Major complications comprised two cases of tumor expulsions, 3 and 6 months after embolization, without any sequelae; and one case of readmission in group B as a result of persistence of severe pain. There were two patients older than 50 years of age, one from each group, who started a period of amenorrhea after embolization that lasted 5 months.

There were no significant differences between groups in clinical outcomes 6 months after the procedure ($P > 0.99$ and $P = .72$; Table 4). There was an improvement in menorrhagia in 15 of 17 patients (88.2%) in group A and 18 of 20 patients (90.0%) in group B, in pain in eight of nine patients (88.8%) in both groups, and in bulk-related symptoms in four of five patients (80.0%) in group A and three of four patients (75%) in group B (Table 4).

The mean decreases in uterine and dominant tumor volumes were 34.2% and 49.1% in group A and 28.1% and 43.1% in group B, respectively (Table 5). These differences were not significant ($P = .35$ and $P = .45$, respectively).

DISCUSSION

Based on our experience, pain is the most common side effect and complication after UAE, as also described by other authors (14). It has been well established that acupuncture induces slowly developing general analgesic effects, and these are mediated by various endogenous opioid agents. These findings have been well recognized as the scientific basis of the mechanism of acupuncture.

Table 3
Postembolization Symptoms Other than Pain

Symptom/Outcome	Group A (n = 33)	Group B (n = 37)	P Value
Hospitalization (h)			1.00
4–8 (outpatients)	32	36	
18 (inpatients)	1	1	
Symptoms at discharge			
Fatigue	2 (6.1)	2 (5.4)	>.99
Anorexia	2 (6.1)	2 (5.4)	>.99
Abdominal swelling	2 (6.1)	3 (8.1)	>.99
Vaginal bleeding	2 (6.1)	4 (10.8)	.68
Symptoms the morning after UAE			.27
Fatigue	3 (9.1)	5 (13.5)	.71
Anorexia	3 (9.1)	4 (10.8)	>.99
Vaginal bleeding	3 (9.1)	4 (10.8)	>.99
Abdominal swelling	1 (3.0)	3 (8.1)	.62

Note.—Values in parentheses are percentages.

* Mann-Whitney *U* test.**Table 4**
Clinical Outcome of UAE at 6 Months

Symptom	Group A (n = 31)		Group B (n = 33)		P Value
	Before UAE	After UAE	Before UAE	After UAE	
Menorrhagia	17	2 (11.8)	20	2 (10.0)	>.99
Pain	9	1 (11.1)	9	1 (11.1)	>.99
Bulk symptoms	5	1 (20.0)	4	1 (25.0)	.72

Note.—Values in parentheses are percentages.

* Fisher exact test.

Table 5
Uterine and Leiomyoma Volumes at 6 Months

Mean Volume (cm ³)	Group A (n = 31)		Group B (n = 33)		P Value*
	Before	After	Before	After	
Uterine	540	282	445	262	.35
Dominant tumor	210	61.2	134	68.4	.45

* Student *t* test.

ture until now (15). Acupuncture analgesia is the result of physiologic and neuropharmacologic processes induced by afferent inputs excited by acupuncture, and the participation of various endogenous opioid agents and receptors in EAA has been widely accepted (16).

EAA produces a gradual development of general analgesic effects of sustained duration (17). EAA of high inten-

sity and low frequency has been assumed to be the typical parameter for EAA mediated by endogenous opioid agents (18).

Only the experience of the acupuncturist and the acupuncturist's knowledge of acupoints are the decisive factors for analgesic procedure details. A long course is required to acquire the skills to perform electroacupuncture. The World Health Organization recom-

mends a 300-hour course for physicians to understand the mechanisms applied in acupuncture. The equipment required are needles and a low-frequency electrostimulator, which costs \$700. The additional time required to prepare the patients for acupuncture is 20–30 minutes. The monitoring needed for electroacupuncture is the same required for any intervention. The most important points for anesthesia of abdominal organs are ST 36, located in the upper third of the internal face of the leg, and SP 6, located in the lower third of the external face of the leg. The needles are placed at the most important points for abdominal anesthesia: ST 36 and SP 6, through which the meridian of the abdominal organs pass. The anesthesia achieved by electroacupuncture is stronger and more efficient than that achieved with single acupuncture. There are no known risks or complications associated with EAA.

We tried to evaluate whether EAA is a safe and effective alternative to the use of antiinflammatory and analgesic pharmacologic sedation/analgesia in UAE for uterine fibroids.

We found no differences in puncture site pain between groups. During the procedure, eight patients reported light pain in group A (24%), and 14 patients reported light or moderate pain in group B (38%), which is in accordance with the findings of Pron et al (14), who reported a 30% incidence of intraprocedural pain. Despite our sedative/analgesic medications and careful patient monitoring, there was still a significant proportion of patients who reported intraprocedural pain or discomfort. Despite this fact, the intensity of pain during UAE was very low in both groups, with no patients in group A reporting pain more intense than light pain and only four patients in group B reporting moderate pain. The mean pain scores during UAE (scale, 0–10) were 0.36 in group A and 0.84 in group B. We tried to see if electroacupuncture could relieve this problem and compare its results versus those of our routine medication approach. We found some small differences between groups, with 76% of patients treated under electroacupuncture (ie, group A) reporting no intraprocedural pain, versus 62% of patients treated under local anesthesia (group B). The degree of pain in patients treated under EAA was lower

than in patients treated under local anesthesia despite fewer medication and lower doses of antiinflammatory and analgesic medication used in group A. These differences were not statistically significant. Similarly, Ding and Gu (19) found that acupuncture/general anesthesia reduces the consumption of narcotic agents during surgery.

From our experience, the most intense pain reported by patients treated with UAE occurs during the first 4 hours after embolization. Worthington-Kirsch and Koller (10) found that pain experienced after embolization follows a consistent pattern over time, increasing during the first 2 hours after the procedure and then remaining stable for several hours. Afterward, pain decreases fairly rapidly to a much lower level. As shown by our results, the maximum intensity pain in both groups was found during the first hours after embolization (ie, before discharge), with mean pain scores of 3.00 in group A and 4.49 in group B ($P = .0001$). The most intense pain reported by patients was during this time period, with 13 patients from group B referring severe or very severe pain, compared with two patients from group A. However, two patients from group B were discharged despite their severe pain for personal reasons. These differences between groups were statistically significant ($P = .02$). At discharge and the morning after UAE, the mean pain scores were lower in both groups, proving this tendency of decreasing pain intensity over time.

There were only two patients treated as inpatients (one in each group) as a result of severe or very severe pain at the time of discharge (8 hours after UAE). As stated by other authors (5), pain intensity is very unpredictable and variable among patients. We could not find a plausible explanation for this more intense pain reported by these patients. There is no proven relationship between pelvic pain after UAE and the size of the uterus or the number, location, or size of leiomyomas (5). However, there seems to be some correlation between the extent of embolization and pain after UAE (20). The endpoint chosen for embolization was slow flow or near-stasis in the main uterine artery, as reported by other authors (21). We applied this endpoint of embolization equally in both groups, as proven by the

amount of PVA particles used per patient (2.8 mg in group A and 2.7 mg in group B). We found no significant differences between groups in uterine volume ($P = .52$), dominant leiomyoma volume ($P = .39$), number of tumors ($P = .68$), or tumor location ($P = .59$).

There were no significant differences between groups at 6-month follow-up ($P = .35$ and $P = .45$). There were persisting symptoms of menorrhagia in two patients in each group and bulk-related symptoms and pain in one patient from each group.

The present study has some limitations. It is not randomized, and neither patients nor operators were blinded to the technique used, which can induce some bias. The assignment to treatment was based on patient preference. This introduces the possibility that patients' views of acupuncture may have entered into the choice of therapy. This raises the possibility that there could be an additional placebo effect in the EAA group.

In addition, the groups were also not completely homogenous. There was a significant difference between groups in mean age ($P = .015$). Patients from group A were younger on average, perhaps because younger subjects are generally more receptive to new treatment options as EAA.

Although patients in group A (ie, EAA) had no analgesic medication just before and during UAE and received only half the doses on finishing the procedure, they still received antiinflammatory drugs before and after discharge. Therefore, patients in group A still had some analgesic and antiinflammatory medication, although in much lower doses.

Further prospective studies with randomized selection of patients comparing standard therapy, standard electroacupuncture, and electroacupuncture with the needles in nonstandard locations (ie, "sham electroacupuncture") would be important to clearly demonstrate its clinical effectiveness.

In conclusion, although our findings are preliminary, they suggest that EAA may be effective in reducing pain after embolization. These findings must be confirmed with a randomized trial before definitive conclusions can be drawn. Electroacupuncture may be an effective alternative to the use of pharmacologic sedation/analgesia during UAE.

References

1. Volkers NA, Hehenkamp WJ, Smit P, Ankum WM, Reekers JA, Birnie E. Economic evaluation of uterine artery embolization versus hysterectomy in the treatment of symptomatic uterine fibroids: results from the randomized EMMY trial. *J Vasc Interv Radiol* 2008; 19:1007-1016.
2. Lohle PN, Voogt MJ, De Vries J, et al. Long-term outcome of uterine artery embolization for symptomatic uterine leiomyomas. *J Vasc Interv Radiol* 2008; 19:319-326.
3. Goodwin SC, Spies JB, Worthington-Kirsch R, et al. Fibroid Registry for Outcomes Data (FIBROID) Registry Steering Committee and Core Site Investigators. Uterine artery embolization for treatment of leiomyomata: long-term outcomes from the FIBROID Registry. *Obstet Gynecol* 2008; 111:22-33.
4. Spies JB, Spector A, Roth AR, Baker CM, Skrynarz LM, Skrynarz KM. Complications after uterine artery embolization for leiomyomas. *Obstet Gynecol* 2002; 100:873-880.
5. Roth AR, Spies JB, Walsh SM, Wood BJ, Gomez-Jorge J, Levy EB. Pain after uterine artery embolization for leiomyomata: can its severity be predicted and does severity predict outcome? *J Vasc Interv Radiol* 2000; 11:1047-1052.
6. Bruno J, Sterbis K, Flick P, et al. Recovery after uterine artery embolization for leiomyomas: a detailed analysis of its duration and severity. *J Vasc Interv Radiol* 2004; 15:801-807.
7. Al-Fozan H, Dufort HJ, Kaplow M, Valenti D, Tulandi T. Cost analysis of myomectomy, hysterectomy, and uterine artery embolization. *Am J Obstet Gynecol* 2002; 187:1401-1404.
8. Ryan JM, Gaaney M, Glasson J, Doherty J, Smith TP. Simplified pain-control protocol after uterine artery embolization. *Radiology* 2002; 224:610-611.
9. Baerlocher MO, Asch MR, Hayeems EZ, Rajan DK. Uterine artery embolization-inpatient and outpatient therapy: a comparison of cost, safety, and patient satisfaction. *Can Assoc Radiol J* 2006; 57:95-105.
10. Worthington-Kirsch RL, Koller NE. Time course of pain after uterine artery embolization for fibroid disease. *Medscape Womens Health* 2002; 7:4.
11. Witt CM, Reinhold T, Brinkhaus B, Roll S, Jena S, Willich SN. Acupuncture in patients with dysmenorrhea: a randomized study on clinical effectiveness and cost-effectiveness in usual care. *Am J Obstet Gynecol* 2008; 198:166.e1-e8.
12. Proctor ML, Smith CA, Farquhar CM, Stones RW. Transcutaneous electrical nerve stimulation and acupuncture for primary dysmenorrhoea. *Cochrane Database Syst Rev* 2002; CD002123.

13. Sacks D, McClenny TE, Cardella JF, et al. Society of Interventional Radiology clinical practice guidelines. *J Vasc Interv Radiol* 2003; 14(suppl): S199–S202.
14. Pron G, Mocarski E, Bennett J, et al. Tolerance, hospital stay, and recovery after uterine artery embolization for fibroids: the Ontario Uterine Fibroid Embolization Trial. *J Vasc Interv Radiol* 2003; 14:1243–1250.
15. Han JS. Acupuncture: neuropeptide release produced by electrical stimulation of different frequencies. *Trends Neurosci* 2003; 26:17–22.
16. Kawakita K, Okada K. Mechanisms of action of acupuncture for chronic pain relief - polymodal receptors are the key candidates. *Acupuncture Med* 2006; 24(suppl):S58–S66.
17. Pomeranz B, Chiu D. Nalzone blockade of acupuncture analgesia: endorphin implicated. *Life Sci* 1976; 19:1757–1762.
18. Kawakita K, Funakoshi M. Suppression of the jaw-opening reflex by conditioning Ao fibre stimulation and electroacupuncture in the rat. *Exp Neurol* 1982; 78:461–465.
19. Ding YH, Gu CY. Effect of acupuncture-general anesthesia on hemodynamics in perioperative period of patients undergoing cholecystectomy. *Zhongguo Zhong Xi Yi Jie He Za Zhi* 2008; 28:206–208.
20. Volkers NA, Hehenkamp W, Birnie E, et al. Uterine artery embolization in the treatment of symptomatic uterine fibroid tumors (EMMY trial): periprocedural results and complications. *J Vasc Interv Radiol* 2003; 17:471–480.
21. Spies JB, Bruno J, Czeyda-Pommersheim F, Magee ST, Ascher SA, Jha RC. Long-term outcome of uterine artery embolization of leiomyomata. *Obstet Gynecol* 2005; 106:933–939.